

Autoantibodies to intrinsic factor can jeopardize pernicious anemia diagnosis: a case report

Lucía Fraile, Ana Sopena, Carlos E. Chávez,
Maria Font-Font, Aureli Esquerda

Servicio de Análisis Clínicos, Hospital Universitari Arnau de Vilanova, Lleida, Spain

ARTICLE INFO

Corresponding author:

Lucía Fraile García
Servicio de Análisis Clínicos
Hospital Universitari Arnau de Vilanova
Avenida Rovira Roure 80
25198. Lleida
Spain
Phone: +34 691754564
E-mail: lucia.cuellar96@gmail.com

Key words:

vitamin B12, cobalamin,
pernicious anemia, interference

ABSTRACT

Vitamin B12 deficiency may cause neurological and hematological alterations. Its assessment should be easy considering that the access to its measurement is available in majority of the clinical laboratories. The presence of technical interference when measuring vitamin B12 can lead to an erroneous or a more difficult diagnosis of conditions as pernicious anemia. We report a case in which an interference in the evaluation of vitamin B12 concentration led to the realization of invasive tests and almost a misdiagnosis of a patient who actually had pernicious anemia. Professionals need to be aware of these interferences when we assess outcomes.

INTRODUCTION

Vitamin B12, or cobalamin, is an essential co-factor that takes part in methylation reactions related to DNA and cell metabolism, such as conversion of methylmalonyl-CoA (MMA) to succinyl-CoA and synthesis of methionine. It is a water-soluble vitamin, which is mostly present in foods of animal origin. Clinical signs of cobalamin deficiency are associated with neurological and hematological symptoms including paresthesia, ataxia, weakness, anemia and pancytopenia (1).

One of the causes of cobalamin deficiency is linked to its malabsorption. Once the cobalamin is ingested, it is absorbed in the ileum thanks to the intrinsic factor, which is bound to it and is secreted in the gastric juice by the parietal cells. Intrinsic factor is required for absorption of vitamin B12. There are different causes that can explain this malabsorption, like gastrectomy, surgical resections, and a variety of bacterial or inflammatory diseases affecting the small intestine. However, the most common cause is a defect in the secretion of intrinsic factor due to the presence of autoantibodies, either because of antibodies to parietal cells or to the intrinsic factor itself, resulting in an inadequate vitamin B12 absorption from foods. This condition is called pernicious anemia. The prevalence of pernicious anemia is 0.1% in the general population and 2-3% in individuals over the age of 65 (female:male ratio ~ 2:1) (2).

Vitamin B12 could be measured by different methods, based on competitive binding immunoassays (Figure 1). In our laboratory, the determination of Vitamin B12 was done by Access Vitamin B12 assay (Beckman Coulter) (Figure 1A). It has an initial denaturation step that inactivates intrinsic factor blocking antibodies that can be present in the patient's serum. Approximately 50% of

patients with pernicious anemia have these anti-intrinsic factor antibodies. The vitamin B12 present in the sample binds to the intrinsic factor-alkaline phosphatase conjugate, preventing the conjugate from binding to the solid phase anti-intrinsic factor. The chemiluminescent substrate is added to the vessel and light generated by the reaction is measured with a luminometer. The amount of light is the result of the reaction produced by the non-vitamin B12 bound conjugate bound to the solid phase, and is inversely proportional to the concentration of vitamin B12 concentration in the sample.

Even though the demonstration of vitamin B12 deficiency is one of the main aspect for the diagnosis, it has been proved that measuring serum vitamin B12 level alone is not sufficient to diagnose the deficiency and its sensitivity is questionable. This is caused by an analytical interference in the vitamin B12 measurement that has been reported in various publications (3–5). Therefore, the evaluation of MMA and homocysteine levels, as functional biomarkers of vitamin B12 deficiency, is recommended to evaluate the diagnosis (6).

We report a case in which the diagnosis of pernicious anemia was complicated due to an erroneous result in the measurement of vitamin B12 that made the diagnosis more difficult and led to indication of more diagnostic tests and a possible misdiagnosis.

CLINICAL - DIAGNOSTIC CASE

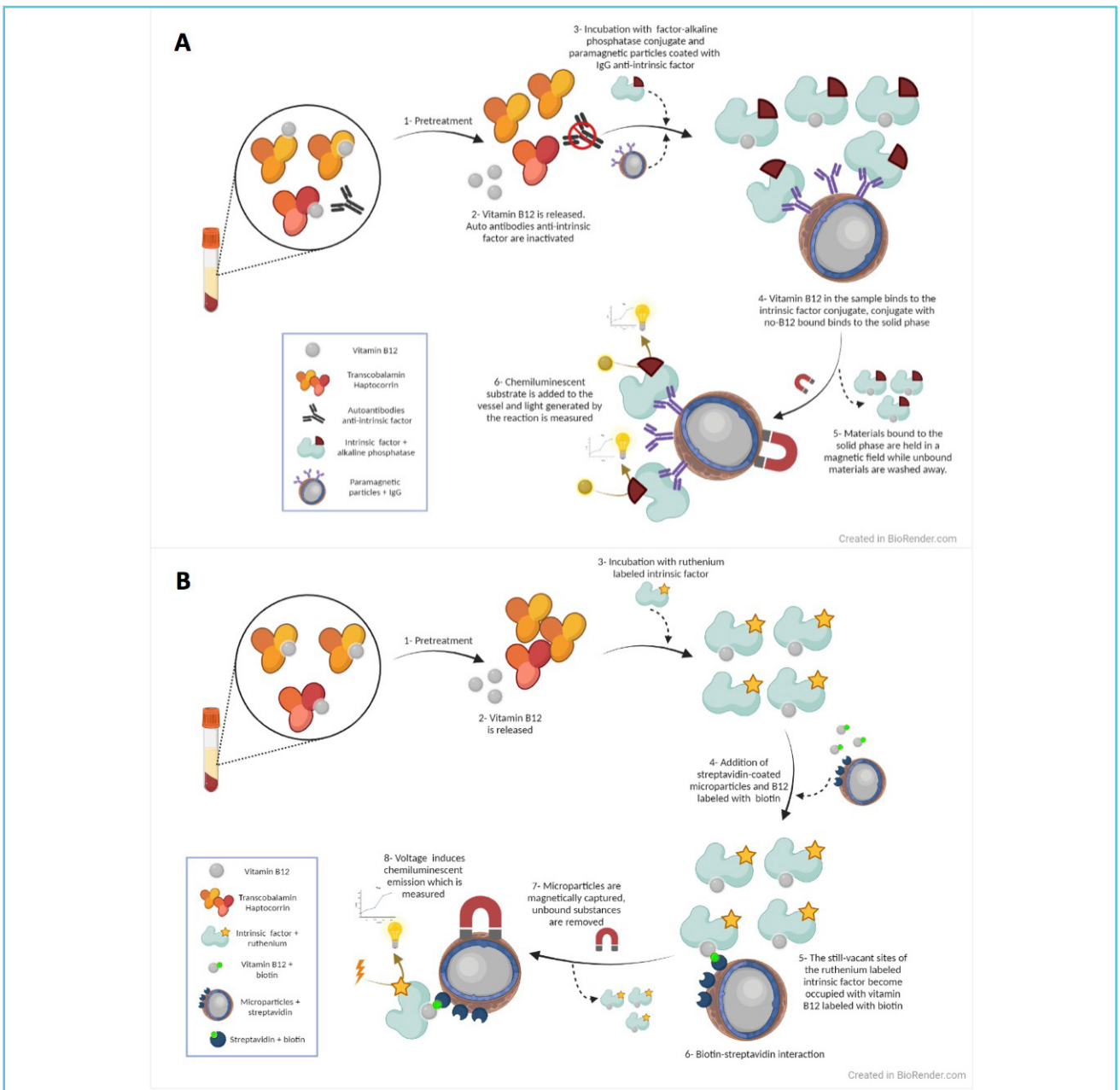
An 86-year-old woman with antecedents of arterial hypertension, type-II diabetes mellitus and paroxysmal atrial fibrillation, was referred for a hematological evaluation due to macrocytic anemia and leukopenia. The analytical results obtained were: leukocytes $3.71 \times 10^9/L$ [reference range (RR): 4.8-10.8], red blood cells $2.6 \times 10^{12}/L$ [RR: 4-5.4], hemoglobin 107 g/L

Figure 1

Comparing different methods for vitamin B12 measurement:

A) Access Vitamin B12 assay by Beckman Coulter®. It represents a chemiluminescent immunoassay based on the binding of the conjugate to solid phase anti-intrinsic factor. The light production is inversely proportional to the concentration of vitamin B12 in the sample.

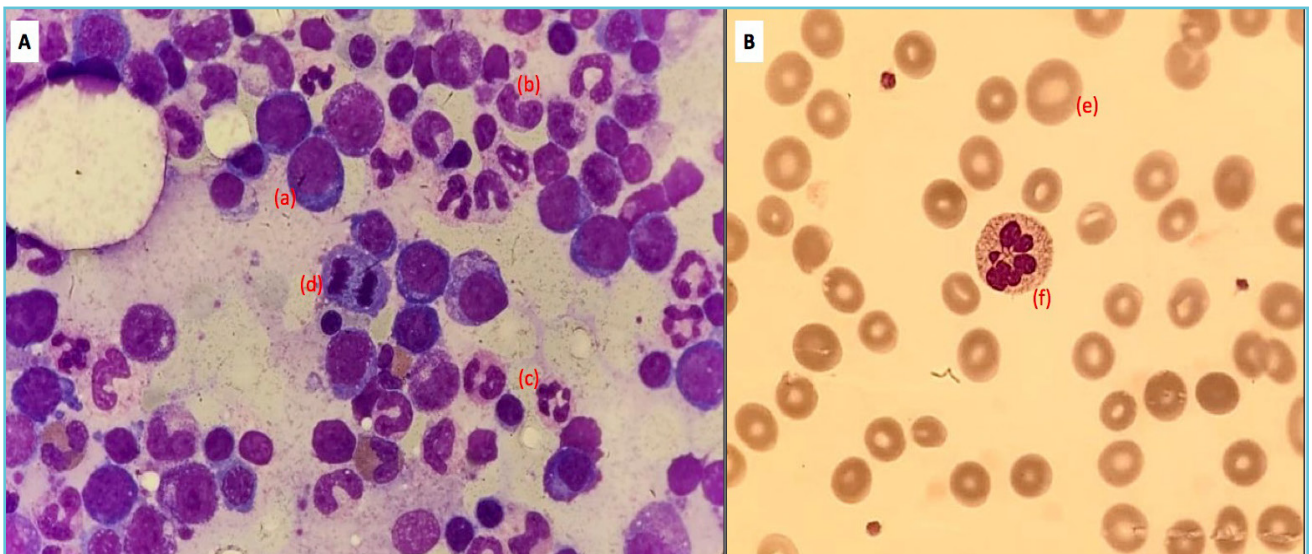
B) Vitamin B12 assay by cobas Roche®. It represents an electrochemiluminescence immunoassay based on biotin-streptavidin binding. The light production is inversely proportional to the concentration of vitamin B12 in the sample.



[RR: 120-160], MCV 116 fL [RR: 80-100], MCH 41.2 pg [RR: 26-34], vitamin B12 269 pmol/L [RR: 133-675] and folic acid >53 nmol/L [RR: 7-41.5]. The most probable diagnosis would be megaloblastic anemia as a result of cobalamin or folic acid deficiency, but since no such deficiency was observed, these results suggested a low-risk myelodysplastic syndrome, and a check-up was performed after three months. These new results showed a clinical deterioration with significant asthenia: leukocytes $3.8 \times 10^9/L$ [RR: 4.8-10.8], hemoglobin 95 g/L [RR: 120-160], MCV 128 fL [RR: 80-100], and low reticulocytes. A bone-marrow aspirate and a biopsy were performed because of a suspicion of a bone-marrow insufficiency. The bone-marrow study did not reveal any dysplastic features in any hematological series, but manifested megaloblastic features (Figure 2A): red blood cells and their progenitors were macrocytic and we could observe several mitosis and vacuoles,

Howell-Jolly bodies, some binucleated cells and 0.89 % of blasts. Cytomorphology of peripheral blood (Figure 2B) also suggested a megaloblastic anemia (macroovalocytes and hypersegmented neutrophils) but with the discordance of non-decreased values of vitamin B12 or folic acid. In addition, the patient had a polyclonal increase of immunoglobulins and, in order to establish a clear diagnosis, the laboratory specialists started to consider a technical interference, initially due to this high titer of immunoglobulins. Therefore, serum immunoglobulins were precipitated by adding polyethylene glycol (PEG) in a 1:1 dilution with serum, after which vitamin B12 was measured again, showing a lower level below the reference value (Table 1). With this high suspicion of a megaloblastic anemia and a very possible interference, a measurement of autoantibodies to intrinsic factor and parietal cells, MMA, homocysteine and the evaluation of vitamin B12 was

Figure 2 A) Bone marrow aspirate with megaloblastic features: macrocytic red blood cells and its progenitors (a), giant band neutrophils (b), hypersegmented neutrophils (c) and mitosis (d). 1000x, May-Grünwald-Giemsa stain. B) Peripheral blood suggesting a megaloblastic anemia: macroovalocytes (e) and a hypersegmented neutrophil (f). 1000x, May-Grünwald-Giemsa stain.



performed in another clinical laboratory with a different analytical method (electrochemiluminescence immunoassay “ECLIA” at Cobas e of Roche®) (Table 1, Table 2).

These new results confirmed vitamin B12 deficiency, which was not evident with our analytical method, because of the presence of antibodies to the intrinsic factor. The patient was treated with cyanocobalamine (Optovite B12®)

and she was reevaluated revealing clinical and analytical improvement.

DISCUSSION

The deficiency of vitamin B12 is relatively common and it may result in a variety of clinical symptoms (1). In case of a severe deficiency, it can present as bone marrow suppression resulting in anemia, neutropenia and/or thrombocytopenia. Its demonstration should be easy,

Table 1 Test results for vitamin B12 evaluation by different techniques and/or pretreatments

Equipment	Vitamin B12 result
UniCel Dxl 800 Beckman Coulter ®	269 pmol/L
UniCel Dxl 800 Beckman Coulter ® (1:1 dilution with PEG)	<37 pmol/L
cobas e 601 Roche ®	37 pmol/L

Table 2 Test results for the diagnosis of pernicious anemia*

	Result	Reference range
Vitamin B12	37 pmol/L	133 - 675
Homocysteine	100.84 µmol/L	4.3 - 11.1
Methyl-malonic acid (MMA)	13.7 µmol/L	0.08 - 0.56
Antibodies to intrinsic factor	>600 U/mL	0 - 7
Antibodies to parietal cells	negative	

* Vitamin B12 measured by an electrochemiluminescence immunoassay in a cobas 6 601 Roche®, homocysteine measured by immunoturbidimetry, MMA measured by mass spectrometry, antibodies to intrinsic factor measured by fluoroenzyme immunoassay and antibodies to parietal cells determined by indirect immunofluorescence. Reference ranges are provided.

because it is a routine parameter that can be measured in the majority of clinical laboratories, but this may not always be the case.

In very rare cases, during the pretreatment and measurement of vitamin B12, certain samples may not be inactivated because of the heterogeneity or extremely high titer of the anti-intrinsic factor antibodies. Such interfering autoantibodies may give erroneous results, as we have seen in the reported case. This situation has been described in other cases or studies and associated with different analyzers (5). This fact is most probably due to an ineffective inactivation of interfering anti-intrinsic factor auto-antibodies and its binding to the conjugate, although it can also be produced by other immunoglobulins.

This interference can have an important impact for both diagnosis and treatment. We report a case in which the suspicion of a pernicious anemia that cannot be confirmed has revealed a significant interference. It causes falsely high or normal levels of vitamin B12 in a patient with an actual deficiency. The deficiency could not be proved and the diagnosis was oriented as a possible myelodysplastic syndrome, even requiring a bone marrow study to confirm the pathology. We think that it is important for laboratory and clinical specialists to be aware of this interference or technical limitation. Patients should be given a further assessment if they are suspected of having these auto-antibodies or if the results of vitamin B12 conflict with other clinical or laboratory findings. This must be taken into consideration and confirmed by additional tests prior to performing invasive procedures such as bone marrow aspiration or initiating treatment. We suggest evaluating the presence of anti-intrinsic factor antibodies, given the possibility of this technical interference. As we discussed above, it is necessary to use metabolic tests such as the measurement of homocysteine and/or MMA in patients strongly suspected to have a pernicious anemia without a low cobalamin

level (6). It is said that these parameters should always accompany cobalamin concentration, or the performance of the evaluation of vitamin B12 with other techniques, like mass spectrometry, although it is not available in the majority of the laboratories yet.

TAKE HOME MESSAGES / LEARNING POINTS

- Laboratory specialists play a key role in the detection of technical interferences during the evaluation of some parameters, especially in immunoassays.
- A misdiagnosis of a pernicious anemia could raise suspicion of a hematological disease, which may lead to invasive diagnostic procedures and treatment that are unnecessary for the patient.
- The measurement of homocysteine and MMA, together with vitamin B12 concentration, is highly recommended if we have a suspicion of pernicious anemia.



Conflicts of interest

None of the authors have any conflict of interest to report.

Funding

This research received no specific grant from any funding agency in the public, commercial, or not-for-profit sectors.

Contributorship

LF researched the literature, wrote and edited the manuscript, AS reviewed and corrected the manuscript. All authors reviewed and approved the final version of the manuscript.

REFERENCES

1. Hunt A, Harrington D, Robinson S. Vitamin B12 deficiency. *BMJ*. 2014 Sep 4;349:g5226.
2. Esposito G, Dottori L, Pivetta G, Ligato I, Dilaghi E, Lahner E. Pernicious Anemia: The Hematological Presentation of a Multifaceted Disorder Caused by Cobalamin Deficiency. *Nutrients*. 2022 Apr 17;14(8):1672.
3. Yang DT, Cook RJ. Spurious Elevations of Vitamin B12 with Pernicious Anemia. *N Engl J Med*. 2012 May 3; 366(18):1742–3.
4. van Rossum AP, Vlasveld LT, Castel A. Falsely elevated cobalamin concentration in multiple assays in a patient with pernicious anemia: a case study. *Clin Chem Lab Med*. 2013 Sep;51(9):e217-9.
5. Ralph C, Pal AY. Failures of Cobalamin Assays in Pernicious Anemia. *N Engl J Med*. 2012 Jul 26;367(4): 385–6.
6. İspir E, Serdar MA, Ozgurtas T, et al. Comparison of four automated serum vitamin B12 assays. *Clin Chem Lab Med*. 2015 Jul;53(8):1205-13.